

Role of Autologous Adipose Tissue and Adipose-derived Regenerative Cell Grafts

Breast reconstruction is an important procedure that is increasingly being made available to patients undergoing total or partial mastectomy. As a result of improved diagnostics, breast conserving surgery followed by radiation therapy has replaced modified radical mastectomy as the most common treatment for early-stage breast cancer. However, this procedure frequently creates a deformity that can be difficult to repair using conventional techniques that employ implants. To overcome the limitations of implants as well as other reconstructive approaches that utilize tissue flaps, a new procedure that employs grafts of autologous adipose tissue combined with adipose-derived regenerative cells (ADRCs) has been developed. This graft procedure can be used as an adjunct to traditional implants and tissue flap techniques and also has the potential to be used as the principal therapy. Meanwhile clinical results from partial mastectomy patients that utilize grafts of autologous adipose tissue enriched with ADRCs show improvement in breast contour, fibrosis (scarring), pigmentation, and skin quality.

This short review provides an overview of traditional breast reconstruction techniques and their limitations. It also presents the experimental and clinical data with autologous adipose tissue and ADRCs grafts and their role in fulfilling an unmet medical need in breast reconstruction following cancer therapy.

INTRODUCTION

More than one million women worldwide are diagnosed with breast cancer annually¹. In recent years the standard therapy for patients with early localized breast cancer has changed from total mastectomy to breast conserving approaches frequently supplemented with local radiation

therapy². Numerous clinical trials have shown that partial mastectomy, which includes quadrantectomy or lumpectomy, is as effective as total mastectomy for patients with localized disease³. This approach frequently results in postoperative breast asymmetry and painful scarring due to distortion, retraction, and noticeable volume changes in the breast, or to changes in the position of the nipple and areola complex⁵. In many patients these problems lead to dissatisfaction with the aesthetic appearance of their breasts and can have a major impact on their psychological well being and quality of life^{6, 7}. Adjunctive radiation treatment can add to the problem by inducing avascular fibrosis, retraction, and atrophy of remaining breast tissue and the underlying chest wall, as well as hypo- or hyper-pigmentation, telangiectasia and atrophy of breast skin⁵.

Breast reconstruction is increasingly being offered to patients in an effort to reduce the aesthetic and psychological consequences of mastectomy or the postoperative breast deformation that is often an outcome of lumpectomy. A number of different approaches for reconstruction are used although the precise combination used for a particular patient is dependent upon factors such as age, disease state, body habitus, and lifestyle. For example, immediate breast reconstruction, which is carried out at the same time as total or partial mastectomy, has the advantage that the chest tissue is not damaged by radiation therapy and often has superior aesthetic outcome with fewer complications⁸. It may also be followed up with secondary procedures to complete the reconstruction process. Delayed reconstruction may be a better option for patients undergoing radiation therapy in order to avoid radiation-induced impairment of healing.

CONVENTIONAL BREAST RECONSTRUCTION

Traditionally, women have had the option of breast reconstruction using tissue expanders and breast implants, autologous reconstruction using a flap of their own tissue, or a combination of both².

Implant procedures typically commence with the insertion of a tissue expander, a temporary implant, beneath a pocket under the pectoralis major muscle of the chest wall⁹. The pectoral muscle may be released along its inferior edge to allow a larger, more supple pocket for the expander at the expense of thinner lower pole soft tissue coverage. In a minimally invasive, outpatient procedure that can take weeks or months, saline solution is injected percutaneously to gradually expand the overlying tissue. Once the expander has reached the intended size, it may remain as the final implant or be removed and replaced with a more permanent implant.

These implants are typically a silicone rubber shell filled with saline or silicone and can vary greatly in contour, texture, and the placement of the incision. Saline implants can have either a fixed volume or can be adjusted after implantation⁹. Silicone implants filled with silicone gel have a consistency more similar to human fat tissue. However, use of this approach following breast conserving therapy is complicated by the irregular size, shape, and position of the breast contour defect such that it is often extremely difficult to identify an implant that matches the defect. Even with more extensive surgery, for example, those in which only the skin and nipple areola complex is spared, the outcome following use of implants can be complicated by difficulties matching the plane of the conserved skin and the expanded underlying muscle such that window-shading and other

contour defects can occur⁸. The paucity of residual subcutaneous tissue can also cause problems with both implant loss and tissue necrosis^{11, 12}.

Tissue flap procedures, such as *latissimus dorsi* and TRAM flaps, are also used in breast reconstruction following total or partial mastectomy¹⁰. Radiation can increase the risk for complications as a result of its effects on wound healing¹³. It can also affect symmetry with the other breast and can alter capsule formation and increase the rate of capsular contraction^{14,15}. As with any flap procedure, donor site morbidity can also be a problem in some patients¹⁶.

NOVEL BREAST RECONSTRUCTION TECHNIQUE – AUTOLOGOUS ADIPOSE TISSUE WITH ADRCs GRAFTS

Autologous adipose tissue grafting is a commonly performed procedure in reconstructive surgery that has been used for over a century¹⁷. Adipose tissue has many advantages over other soft tissue fillers: it is biocompatible, easily accessible and available, and can produce aesthetically pleasing and natural-looking results. However, significant graft resorption is frequently encountered resulting in unpredictable results¹⁸. To overcome this drawback a novel reconstructive technique has been developed that combines autologous adipose tissue with a population of regenerative cells obtained from the patient's adipose tissue. This approach can be used as the principal therapy or as an adjuvant to traditional implants and tissue flap procedures.

RATIONALE BEHIND ADIPOSE TISSUE CELL-ENRICHMENT

Harvest of adipose tissue, no matter how carefully it is performed, inevitably leads to tissue damage. This can be seen in the presence of free lipid released from ruptured adipocytes present in the waste following washing of a graft or at the top of the syringe following centrifugation¹⁹. Once re-implanted the tissue becomes exposed to hypoxic injury until such time as new blood vessels penetrate the graft from adjacent, vascularized tissue²⁰. Thus, graft retention can be improved by applying approaches that minimize these traumatic and hypoxic injuries and that promote local healing and incorporation into adjacent tissue.

In recent years it has become apparent that human adipose tissue contains cells, including adult stem cells, that possess the ability to promote healing and recovery from hypoxic or ischemic injury²¹⁻²⁵. The form of these cells produced without use of cell culture is referred to as ADRCs. ADRCs have been shown to be capable of promoting healing in a number of settings²⁶⁻³⁰. For example, Akita *et al* have shown healing of a refractory chronic wound arising from irradiation following a single treatment with ADRCs^{31,32}. This confirms preclinical data showing ADRC-induced acceleration of healing in an animal model of delayed wound healing³³ and tissue ischemia^{22,25}. On the basis of these and other data it has been proposed that these healing properties might be harnessed to improve graft retention in autologous fat grafting. Indeed, preclinical data show that combining ADRCs with an autologous fat graft effectively doubles graft retention at six and nine months³⁰.

CELL-ENRICHMENT ENHANCES GROWTH FACTOR LEVELS

In fat grafting, the critical area is the interface between the newly grafted tissue and adjacent vascularized tissue. Signals generated by growth factors at this interface modulate incorporation of the graft into recipient site tissues. By boosting the number of regenerative cells at this critical interface, ADRCs increase growth factor signaling and, thereby, improve incorporation. Thus, cell-enrichment increases the number of stem cells at the interface by an average of 28-fold more than grafts prepared by centrifugation (Figure 1; data from Toyoda *et al.*, manuscript in preparation). As shown in Table 1, these cells also dramatically boost growth factor signaling with increases of between 19-fold and 142-fold in different growth factor expression.

These growth factor expression levels are further increased when the graft is implanted and the cells respond to the hypoxic environment *in vivo*. Once the graft has become revascularized and the tissue has become normoxic, growth factor expression returns to normal.

CELL-ENRICHMENT AND RISK OF TUMORS

Naturally, any time a procedure is performed within the breast following malignancy it is important to consider if it might pose a risk by impacting on tumor recurrence. While a number of laboratory studies have shown that cultured stem cells can change the growth or metastatic properties of human breast tumor cell lines^{35,36} it is important to recognize that these studies do not reflect clinical practice³⁷. For example, in these studies the tumor cells are invariably injected into ectopic sites (subcutaneous or under the kidney capsule^{35,36,38,39}) where tumor biology is known to differ in behavior from that at its native site (the breast or mammary fat pad)⁴⁰. Further, these studies use cultured stem cells that are actively proliferating rather than the quiescent cells normally present in adipose tissue.

Clinical experience suggests that fat grafting has no effect on tumor recurrence. Petit *et al*⁴¹ matched two control patients who did not receive fat grafting for each of the 321 patients in their study who were operated on for breast cancer between 1997 and 2008 who also received reconstruction that included fat grafting. No difference in local recurrence rate was seen when evaluating all patients together or when evaluating patients treated with mastectomy or breast conserving surgery only. The only statistically significant difference observed indicated a higher incidence of recurrence for fat grafting patients who had ductal or lobular intraepithelial neoplasia. However, as the recurrence rate for the fat grafting group was consistent with that observed in wider literature^{42,43}, the unusually low rate observed in the control group could be a statistical anomaly. The authors concluded that fat grafting seems to be a safe procedure in breast cancer patients.

To evaluate the effect of fat grafting on tumor recurrence further, including with or without ADRC-enrichment, a clinically relevant *in vivo* preclinical study was performed in which the human breast cancer cell lines ER-negative (MDA-MB-231) and ER-positive (MCF-7) were injected into the mammary fat pad of immunodeficient mice. Human fat grafts were then implanted immediately adjacent to the tumor implant site in order to mirror the worst case clinical scenario in which a fat graft

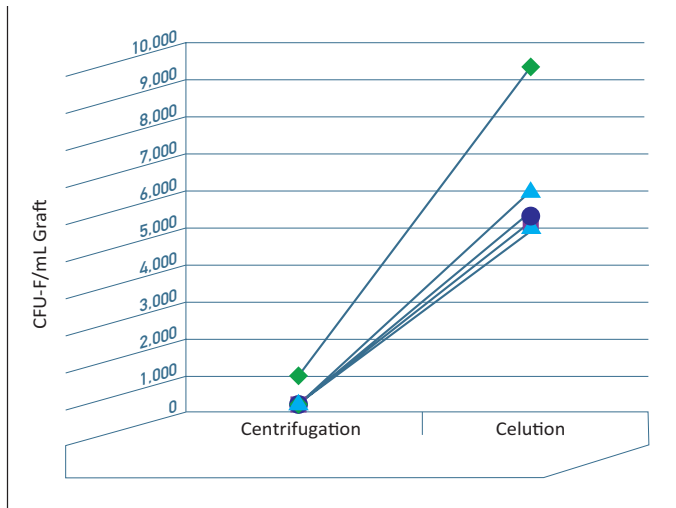


Figure 1. Comparison of stem cell numbers in adipose tissue grafts prepared by centrifugation or Celution using the same harvested tissue. Stem cell assay performed using the CFU-F assay.

Growth Factor	Fold Increase at Interface
Vascular Endothelial Growth Factor (VEGF)	19
Placental Growth Factor (PlGF)	142
Hepatocyte Growth Factor/Scatter Factor (HGF)	30
Platelet-Derived Growth Factor (PDGF)	27
Insulin-like Growth Factor-1 (IGF-1)	75

Table 1: Fold increase in expression levels of key growth factors produced by cells present at the interface of centrifuged grafts and those present in cell-enriched grafts.

is implanted adjacent to an occult tumor. Eight weeks after fat graft implantation the animals were evaluated for tumor frequency, size, and metastasis to the lung. The results showed that fat grafting had no effect, with or without cell-enrichment, on the frequency at which animals developed tumors or metastasis. Fat grafting had no significant effect on tumor size in the ER-negative (MDA-MB-231) cells line and a significant decrease in tumor size with ER-positive (MCF-7) cells (Figure 2)^{44,45}.

EFFICACY AND SAFETY - CLINICAL USE OF ADIPOSE TISSUE AND ADRCs GRAFTS IN BREAST RECONSTRUCTION

Adipose tissue and ADRCs in breast reconstruction:

- As a natural filler for defects after undergoing breast-conserving surgery
- In implant reconstruction to cover the implant with adipose tissue for a more natural appearance
- To correct contour deformities after a flap reconstruction
- In small breasts, to reconstruct the breast following breast-conserving surgery, without the need for large scars and prolonged recovery
- To improve skin quality and soft tissue coverage after mastectomy and radiotherapy

Clinical evaluation of autologous adipose and ADRCs tissue grafts, prepared using the automated

Celution® System, for breast reconstruction in partial mastectomy patients is being carried out in the multi-center RESTORE-2 clinical study. The authors of this study have reported promising interim findings from the first 51 patients at six and 12 months showing excellent graft retention with high levels of patient and surgeon satisfaction^{48,49}. Complications reported to date fall into the same types as those reported previously for fat grafting in the breast⁴⁴. Data also show progressive improvement in scarring, fibrosis, and pigmentation. Previously, a 12 month investigator-initiated clinical study, known as RESTORE-1, was conducted by Kitamura *et al.* used the Celution System for preparation of autologous adipose and ADRCs tissue grafts for breast reconstruction^{46,47} in partial mastectomy patients. Increased graft retention, reduction in scar tissue and increased patient and physician satisfaction when compared to adipose tissue grafts alone were reported. There were no complications reported during or immediately following the procedure and the investigators concluded that autologous adipose tissue and ADRC grafts prepared using the Celution System were safe, effective, and provided durable results with 79% patient satisfaction.

In the related application of breast augmentation, Kamakura *et al*⁵⁰ have reported data in which they measured the difference in chest circumference immediately below the inframammary fold and at the nipple before and after cell-enriched adipose tissue grafting⁵⁰. The data results show an increase

in the breast mound size of approximately 50% one month after the procedure. This declined slightly over the following two months consistent with ongoing absorption of fluid injected with the graft. The outcome stabilized thereafter such that at six and nine month evaluations approximately 90% of the increase detected at one month was retained. Larger, randomized studies are necessary to assess long-term safety and efficacy of this promising new option. Likewise large multi-center clinical studies will be required to assess the efficacy of adipose tissue and ADRCs grafts as a total or adjunct breast reconstruction procedure in patients following total mastectomy.

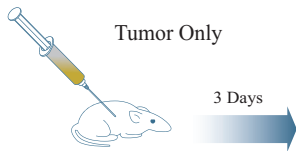CONCLUSION

In summary, the autologous adipose tissue and ADRCs grafts treatment approach has the potential to address a currently unmet clinical need in a large patient population of cancer survivors post breast conservation treatment with or without radiation therapy. The technique harnesses the power of ADRCs and their ability to transiently produce key growth factors that promote healing and adipose tissue retention without stimulating tumor recurrence. This novel breast reconstruction procedure requires less time in the operating theatre as compared to for example a flap procedure and shows significant improvements in repair to the skin and breast tissue and restoration of natural looking breasts with minimal scarring.

Addition of Cell-Enhanced Fat Graft Does Not Increase Tumor Volume in Preclinical Model or Study (MCF-7 ER-Positive Cells)

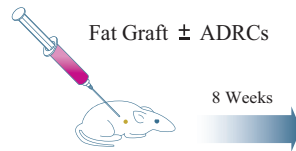
STEP 1

Human MCF-7 breast cancer cell line implanted into right mammary fat pad of SCID mice. All mice also received slow release subcutaneous estrogen implant.

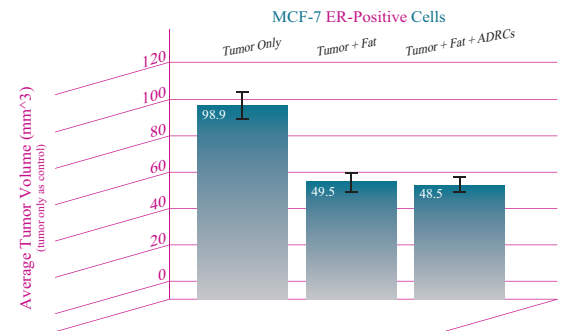


STEP 2

Three days later perform fat grafting with or without Adipose-Derived Regenerative Cells adjacent to tumor cell implantation site.



STEP 3 Euthanize at eight weeks to measure tumor volume



REFERENCES

1. Ferlay J, Parkin DM, Steliarova-Foucher E. GLOBOCAN 2008, Cancer Incidence and Mortality Worldwide: IARC CancerBase No. 10 [Internet] Lyon, France: International Agency for Research on Cancer; 2010.
2. Hamdi M, Wolffi J, Van Landuyt, K. Partial mastectomy reconstruction. *Clin Plastic Surg.* 2007;**34**: 51-62.
3. Fisher B, Anderson S, Bryant J *et al.* Twenty-year follow-up of a randomized trial comparing total mastectomy lumpectomy, and lumpectomy plus irradiation for the treatment of invasive breast cancer. *N Engl J Med* 2002;**347**:1233-1241.
4. Morrow M. Limiting breast surgery to the proper minimum. *Breast* 2005;**14**:523-526.
5. Clough KB, Thomas SS, Fitoussi AD *et al.* Reconstruction after conservative treatment for breast cancer: cosmetic sequelae classification revisited. *Plast Reconstr Surg* 2004;**114**:1743-1753.
6. Moreira H, Canavaro MC. A longitudinal study about the body image and psychosocial adjustment of breast cancer patients during the course of the disease. *Eur J Oncol Nurs* 2010
7. Waljee JF, Hu ES, Ubel PA *et al.* Effect of esthetic outcome after breast-conserving surgery on psychosocial functioning and quality of life. *J Clin Oncol* 2008;**26**:3331-3337.
8. Djohan R, Gage E, Gatherwright J *et al.* Patient satisfaction following nipple-sparing mastectomy and immediate breast reconstruction: an 8-year outcome study. *Plast Reconstr Surg.* 2010;**125**:818-829.
9. Spear SL, Onyewu C. Staged breast reconstruction with saline-filled implants in the irradiated breast: recent trends and therapeutic implications. *Plast Reconstr Surg.* 2000;**105**:930-42
10. Clough K, Kroll S, Audretsch W. An approach to the repair of partial mastectomy defects. *Plast Reconstr Surg.* 1999;**104**:409-420.
11. Salgarello M, Visconti G, Barone-Adesi L. Nipple-sparing mastectomy with immediate implant reconstruction: cosmetic outcomes and technical refinements. *Plast Reconstr Surg.* 2010;**126**:1460-1471.
12. Garwood ER, Moore D, Ewing C *et al.* Total skin-sparing mastectomy: complications and local recurrence rates in 2 cohorts of patients. *Ann.Surg.* 2009;**249**:26-32.
13. Tran NV, Chang DW, Gupta A, Kroll SS, Robb GL. Comparison of immediate and delayed free TRAM flap breast reconstruction in patients receiving postmastectomy radiation therapy. *Plast Reconstr Surg.* 2001;**108**:78-82.
14. Peltoniemi H, Asko-Seljavaara S, Harma M, Sundell B. Latissimus dorsi breast reconstruction. Long term results and return of sensibility. *Scand.J.Plast.Reconstr.Surg.Hand Surg.* 1993;**27**:127-131.
15. Albino FP, Koltz PF, Ling MN, Langstein HN. Irradiated autologous breast reconstructions: effects of patient factors and treatment variables. *Plast Reconstr Surg* 2010;**126**:12-16.
16. Andrades P, Fix RJ, Danilla S *et al.* Ischemic complications in pedicle, free, and muscle sparing transverse rectus abdominis myocutaneous flaps for breast reconstruction. *Ann Plast Surg* 2008;**60**:562-567.
17. Billings E Jr, May JW, Jr. Historical review and present status of free fat graft autotransplantation in plastic and reconstructive surgery. *Plast Reconstr Surg* 1989;**83**:368-381.
18. Kaufman MR, Miller TA, Huang C *et al.* Autologous fat transfer for facial recontouring: is there science behind the art? *Plast Reconstr Surg* 2007;**119**:2287-2296.
19. Pu LL, Coleman SR, Cui X, Ferguson RE, Jr., Vasconez HC. Autologous fat grafts harvested and refined by the Coleman technique: a comparative study. *Plast Reconstr Surg* 2008;**122**:932-937.
20. Nishimura T, Hashimoto H, Nakanishi I, Furukawa M. Microvascular angiogenesis and apoptosis in the survival of free fat grafts. *Laryngoscope* 2000;**110**:1333-8.
21. Hong SJ, Traktuev DO, March KL. Therapeutic potential of adipose-derived stem cells in vascular growth and tissue repair. *Curr Opin Organ Transplant* 2010;**15**:86-91.
22. Feng Z, Ting J, Alfonso Z *et al.* Fresh and cryopreserved, uncultured adipose tissue-derived stem and regenerative cells ameliorate ischemia-reperfusion-induced acute kidney injury. *Nephrol.Dial.Transplant.* 2010
23. Kondo K, Shintani S, Shibata R *et al.* Implantation of adipose-derived regenerative cells enhances ischemia-induced angiogenesis. *Arterioscler Thromb Vasc Biol* 2009;**29**:61-66.
24. Sumi M, Sata M, Toya N *et al.* Transplantation of adipose stromal cells, but not mature adipocytes, augments ischemia-induced angiogenesis. *Life Sci* 2007;**80**:559-565.
25. Miranville A, Heeschen C, Sengenès C *et al.* Improvement of postnatal neovascularization by human adipose tissue-derived stem cells. *Circulation* 2004;**110**:349-355.
26. Ebrahimián TG, Pouzoulet F, Squiban C *et al.* Cell therapy based on adipose tissue-derived stromal cells promotes physiological and pathological wound healing. *Arterioscler Thromb Vasc Biol* 2009;**29**:503-510.
27. Nambu M, Ishihara M, Nakamura S *et al.* Enhanced healing of mitomycin C-treated wounds in rats using inbred adipose tissue-derived stromal cells within an atelocollagen matrix. *Wound Repair Regen* 2007;**15**:505-510.
28. Blanton MW, Hadad I, Johnstone BH *et al.* Adipose stromal cells and platelet-rich plasma therapies synergistically increase revascularization during wound healing. *Plast Reconstr Surg* 2009;**123**:56S-64S.
29. Kim WS, Park BS, Park SH, Kim HK, Sung JH. Antiwrinkle effect of adipose-derived stem cell: activation of dermal fibroblast by secretory factors. *J Dermatol Sci* 2009;**53**:96-102.
30. Park BS, Jang KA, Sung JH *et al.* Adipose-derived stem cells and their secretory factors as a promising therapy for skin aging. *Dermatol Surg* 2008;**34**:1323-1326.
31. Akita S, Akino K, Hirano A, Ohtsuru A, Yamashita S. Mesenchymal stem cell therapy for cutaneous radiation syndrome. *Health Phys* 2010;**98**:858-862.
32. Akita S. Autologous adipose-derived stem cell therapy for chronic radiation injuries. Korea Japan Congress of Plastic and Reconstructive Surgery. 2010:
33. Nambu M, Kishimoto S, Nakamura S *et al.* Accelerated wound healing in healing-impaired db/db mice by autologous adipose tissue-derived stromal cells combined with atelocollagen matrix. *Ann Plast Surg* 2009;**62**:317-321.
34. Zhu M, Zhou Z, Chen Y *et al.* Supplemental of fat grafts with adipose-derived regenerative cells improves long-term graft retention. *Ann Plast Surg* 2010;**64**:222-228.
35. Karnoub AE, Dash AB, Vo AP *et al.* Mesenchymal stem cells within tumour stroma promote breast cancer metastasis. *Nature* 2007;**449**:557-563.
36. Walter M, Liang S, Ghosh S, Hornsby PJ, Li R. Interleukin 6 secreted from adipose stromal cells promotes migration and invasion of breast cancer cells. *Oncogene* 2009;**28**:2745-2755.
37. Fraser JK, Hedrick MH, Cohen SR. Oncologic risks of autologous fat grafting to the breast. *Aesthet.Surg.J.* 2011;**31**:68-75.
38. Muehlberg F, Song YH, Krohn A *et al.* Tissue resident stem cells promote breast cancer growth and metastasis. *Carcinogenesis* 2009
39. Zhang Y, Daquinag A, Traktuev DO *et al.* White adipose tissue cells are recruited by experimental tumors and promote cancer progression in mouse models. *Cancer Res* 2009;**69**:5259-5266.
40. Hoffman RM. Orthotopic metastatic mouse models for anticancer drug discovery and evaluation: a bridge to the clinic. *Invest New Drugs* 1999;**17**:343-359.
41. Petit JY, Botteri E, Lohsriwat V *et al.* Locoregional recurrence risk after lipofilling in breast cancer patients. *Ann. Oncol.* 2011.
42. Dieudonne MN, Bussièrè M, Dos SE *et al.* Adiponectin mediates antiproliferative and apoptotic responses in human MCF7 breast cancer cells. *Biochem.Biophys.Res Commun.* 2006;**345**:271-279.
43. Solin LJ, Kurtz J, Fourquet A, *et al.* Fifteen-year results of breast conserving surgery and definitive breast irradiation for the treatment of ductal carcinoma in situ (intraductal carcinoma of the breast). *J Clin Oncol* 1996;**14**(3):754-763.
44. Morrow M, Strom EA, Bassett LW, *et al.* Standard for the management of ductal carcinoma in situ of the breast (DCIS). *CA Cancer J Clin* 2002;**52**(5):256-276.
45. Jarde T, Caldefie-Chezet F, Goncalves-Mendes N *et al.* Involvement of adiponectin and leptin in breast cancer: clinical and in vitro studies. *Endocr.Relat Cancer* 2009;**16**:1197-1210.
46. Kitamura, K., Teramoto, S., Sugimachi, K., Mori, M., and Hedrick, M. Proposal of new option for breast reconstruction: Adipose-derived stem cell augmented fat transplantation. The 9th Japan-Korea Congress of Plastic and Reconstructive Surgery . 2-22-2008. Okinawa, Japan.
47. Kitamura, H. *Stem cell augmented reconstruction: A new hope for reconstruction after breast conservation therapy.* 2007.
48. Mithoff EM, Perez-Cano R, Vranckx J *et al.* Safety and Feasibility of Autologous Adipose Derived Regenerative Cell-Enhanced Breast Reconstruction Following Partial Mastectomy: Preliminary Results of the RESTORE-2 Clinical Study. 2010:
49. Weiler-Mithoff E, Pérez Cano R, Calabrese C *et al.* Cell-Enhanced Reconstruction after Breast Conservation Therapy: A Proven Technique. *Vol San Antonio Breast Cancer Symposium.* 2009:Abstract 4123.
50. Kamakura T, Ito K. Single treatment autologous breast augmentation with adipose-derived regenerative cells-enriched fat graft [abstract]. *Plastic Reconstr Surg* 2010;**126**:69-70.